

Treatment of Complex Femoropopliteal Lesions Using the Turbo-Power Excimer Laser

Targeting ISR, chronic total occlusions, and heavy thrombus burden with laser atherectomy.

BY EHRIN J. ARMSTRONG, MD, MSc

Excimer laser atherectomy has a number of diverse applications for treatment of complex femoropopliteal lesions. By acting through a unique combination of photochemical, photomechanical, and photothermal mechanisms, excimer laser atherectomy can effectively ablate both mixed morphology and thrombotic lesions in the superficial femoral artery (SFA), popliteal, and infrapopliteal vessels.

The Turbo-Power excimer laser (Spectranetics Corporation) was approved by the US Food and Drug Administration (FDA) in November 2015 for the treatment of infrainguinal de novo and in-stent restenosis (ISR). The device features a 2.3-mm excimer laser fiber pack that is eccentrically offset from a 0.018-inch wire lumen port. Rotation of the device (up to six rotations in each direction) allows the laser to create a larger lumen cross-section area than a standard 2.3-mm laser, and therefore maximize plaque debulking and lesion modification. Another advantage of the Turbo-Power laser is the combined ability to create a pilot channel (using the 2.3-mm laser without rotation), followed by more extensive debulking using the rotational function of the device. The current iteration of the Turbo-Power is 7-F compatible and can be used at a fluence of up to 60 mJ/mm² and frequencies up to 80

Hz. Potential clinical applications of the Turbo-Power system include maximal debulking for treatment of femoropopliteal in-stent restenosis (FP-ISR), modification of complex femoropopliteal lesions, and treatment of large thrombus burden among patients with acute limb ischemia.

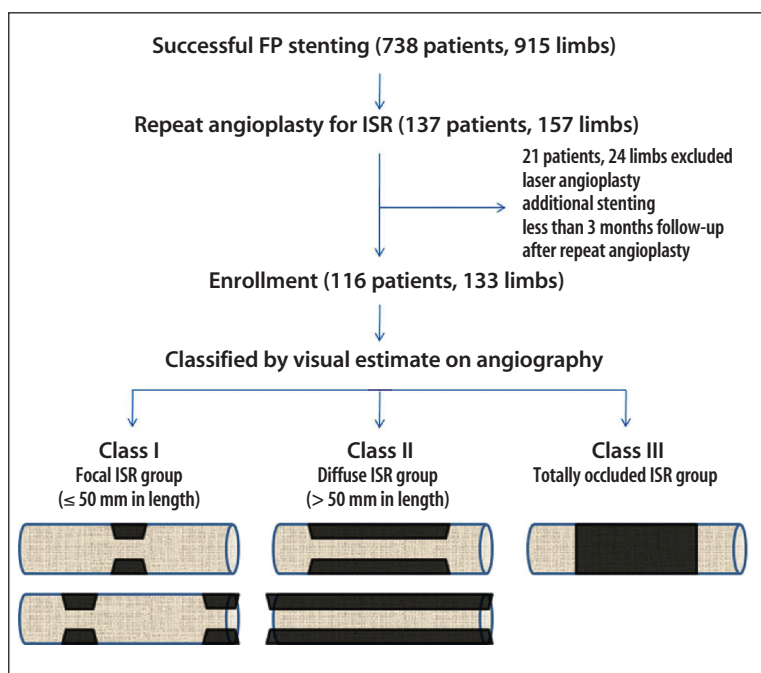


Figure 1. Visual estimate of lesion classification on angiography. Reprinted from J Am Coll Cardiol, Vol 59, Tosaka A, Soga Y, Iida O, et al, Classification and clinical impact of restenosis after femoropopliteal stenting, pg 16-23, Copyright 2012, with permission from Elsevier.¹

FEMOROPOPLITEAL IN-STENT RESTENOSIS

FP-ISR is a common problem associated with high rates of restenosis after balloon angioplasty and/or adjunctive stenting. The Tosaka classification provides a stratification of outcomes for FP-ISR after balloon angioplasty (Figure 1).¹ Tosaka class I FP-ISR, defined as focal stenosis of ≤ 50 mm in length, is associated with relatively high rates of patency after balloon angioplasty, whereas Tosaka class II (diffuse restenosis > 50 mm) and Tosaka class III FP-ISR (in-stent occlusion) are associated with high rates of restenosis after treatment with balloon angioplasty. Additional adjunctive therapies are therefore necessary to optimize the long-term outcomes of patients with FP-ISR.²

Laser atherectomy is an effective and FDA-approved treatment for FP-ISR. The recently published EXCITE-ISR trial was a randomized study of laser atherectomy with adjunctive balloon angioplasty versus balloon angioplasty alone for the treatment of FP-ISR.³ The primary efficacy endpoint of the study was target lesion revascularization at 6 months. The trial demonstrated procedural safety of laser atherectomy, as well as higher rates of acute procedural success. At 6 months, freedom from target lesion revascularization was 73.5% for patients treated with laser atherectomy versus 51.8% for patients treated with balloon angioplasty. Real-world observational data have also confirmed the benefit of laser atherectomy, with the greatest benefit seen among patients with long-segment FP-ISR (Tosaka class II) or in-stent occlusion (Tosaka class III).⁴ Application of the Turbo-Power laser to the treatment of FP-ISR may provide additional benefit to previous excimer laser catheters, as the increased luminal gain with rotational laser atherectomy may more effectively ablate neointima prior to balloon angioplasty or other adjunctive therapies.

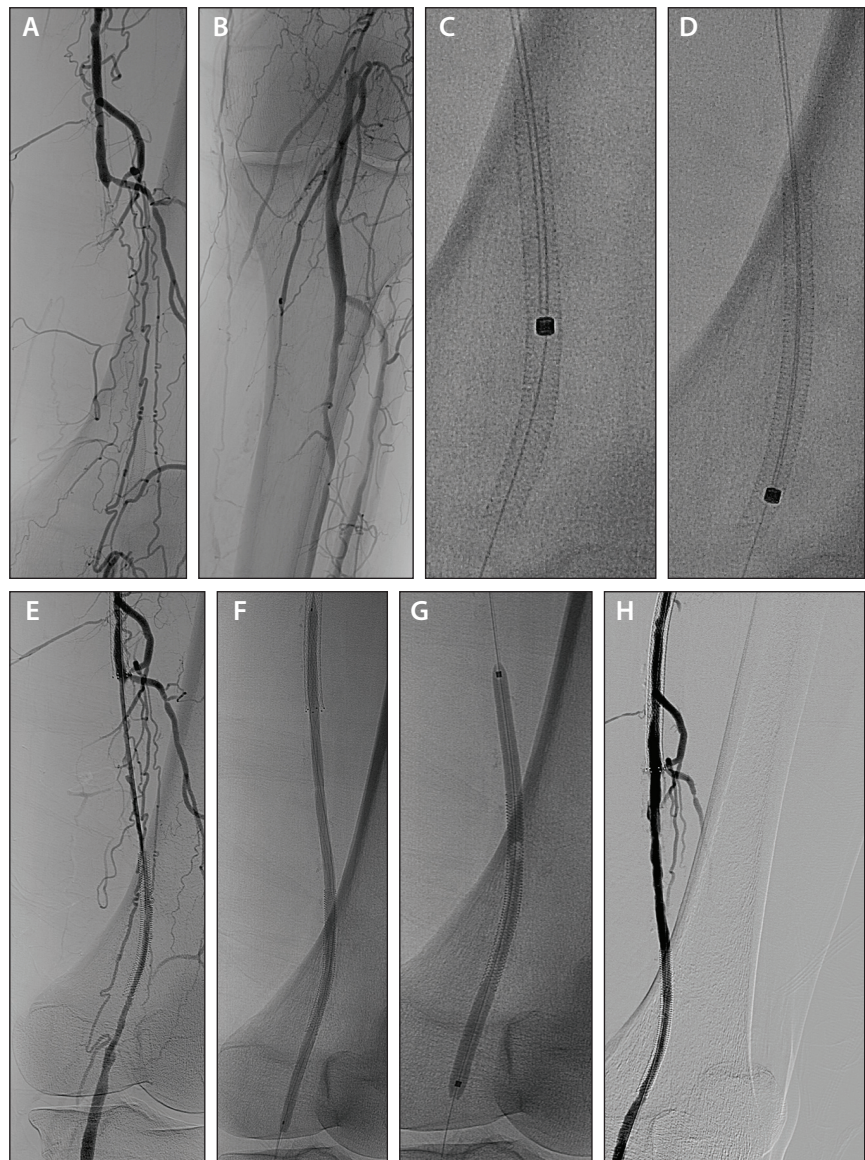


Figure 2. Treatment of femoropopliteal in-stent restenosis with Turbo-Power excimer laser.

Figure 2 illustrates a case of a patient with long-segment FP-ISR due to occlusion of nitinol stents that had been placed 2 years prior in the distal SFA and proximal popliteal artery (Figure 2A and 2B). The FP-ISR segment was successfully crossed with a Treasure 12 0.018-inch wire (Asahi Intecc USA, Inc.). Four quadrant passes were then performed with the Turbo-Power laser at a fluency of 60 mJ/mm² and rate of 60 Hz. Figures 2C and 2D demonstrate the eccentric wire position of the Turbo-Power with rotation; the relative location of the fiber pack to the wire can be used to orient the laser for differential cutting. Subsequent angiography confirmed excellent luminal gain with laser atherectomy (Figure 2E).

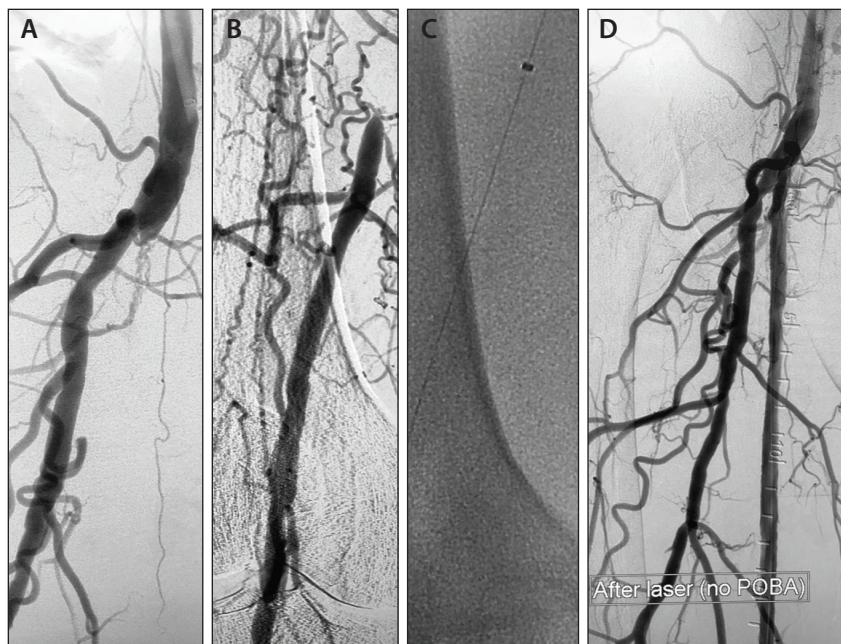


Figure 3. Treatment of a long SFA occlusion with the Turbo-Power excimer laser.

A 5- X 200-mm AngioSculpt balloon (Spectranetics Corporation) was then deployed to maximize stent expansion (Figure 2F), followed by angioplasty with two overlapping 5- X 120-mm In.Pact paclitaxel-coated balloons (Medtronic) (Figure 2G). Final angiography revealed excellent angiographic results with minimal recoil.

The patient remains asymptomatic at 6 months with a patent stent by duplex ultrasound. This case demonstrates the effective role of the Turbo-Power for neointimal ablation.

COMPLEX FEMOROPOPLITEAL OCCLUSIONS

Laser atherectomy has been extensively studied for the treatment of femoropopliteal chronic total occlusions. In many cases, femoropopliteal occlusions have an organized cap at the proximal edge, but softer plaque and semiorganized thrombus in the mid- to distal segment of the occlusion. The application of laser atherectomy to ablate thrombus and mixed morphology may therefore simplify the overall treatment of an otherwise long-segment occlusion. Multiple studies have demonstrated that laser atherectomy is safe and effective for treatment of long-segment femoropopliteal occlusions, with lower rates of bailout stenting compared to balloon angioplasty alone.⁵⁻⁷

Figure 3 demonstrates a case of a 74-year-old man with a history of Rutherford class III claudication despite optimal medical therapy and completion of a walking program. The patient had a proximal occlusion of the SFA (Figure 3A) with reconstitution in the distal

vessel just proximal to Hunter's canal (Figure 3B). The lesion was crossed through the true lumen using a Treasure 12 0.018-inch wire. Laser atherectomy was then performed with four passes of the Turbo-Power laser; each pass was made in a different quadrant (Figure 3C). Subsequent angiography demonstrated dramatic ablation of the lesion with ante-grade flow and minimal dissection throughout the entire course of the SFA (Figure 3D). The patient was then treated with overlapping paclitaxel drug-coated balloons (DCBs). Final angiography revealed preserved three-vessel runoff without any distal embolization. The patient has done well for the past 6 months, without any symptoms of claudication and no evidence of

restenosis by duplex ultrasound.

BYPASS GRAFT OCCLUSION

Excimer laser atherectomy is especially effective at ablating thrombus, based on the observation that the maximal absorption spectrum of thrombus closely overlaps the 308-nm ultraviolet light spectrum of the excimer laser. For this reason, the Turbo-Power laser may be particularly effective for treatment of lesions with large thrombus burden. Possible applications include the use of the Turbo-Power in cases of acute limb ischemia due to stent thrombosis or surgical graft thrombosis. In such cases, use of excimer laser atherectomy may offer advantages over the use of intra-arterial tPA by avoiding the need for lytics and the attendant risk of bleeding.

Figure 4 demonstrates a case of Turbo-Power laser atherectomy for the treatment of bypass graft thrombosis. A 67-year-old man with a past medical history of severe claudication and prior right lower extremity femoropopliteal bypass complicated by graft stenosis 2 years prior presented with acute onset of right lower extremity pain and sensory loss. The patient was taken urgently to the catheterization laboratory, where angiography revealed acute thrombosis of the bypass graft and chronic occlusion of the patient's native SFA, with reconstitution via collaterals in the below-knee popliteal artery (Figures 4A and 4B). A Turbo-Power laser was used at a fluence of 60 mJ/mm² and rate of 60 Hz throughout the approximately 400-mm length of the

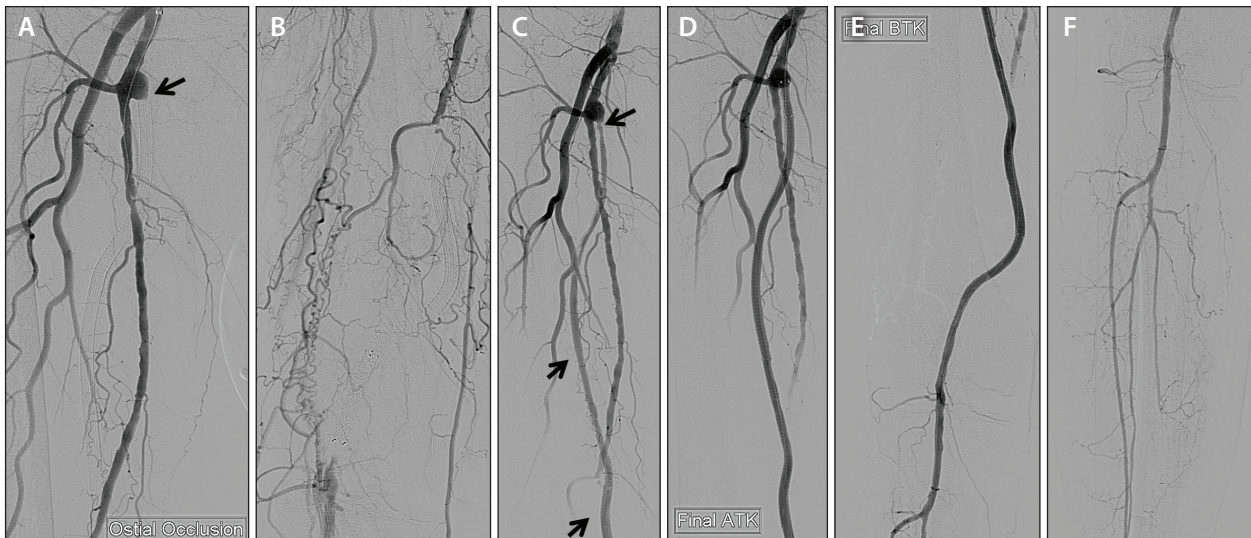


Figure 4. Treatment of a thrombosed bypass graft with the Turbo-Power excimer laser.

graft, with a total of four directional passes. Subsequent angiography revealed significant ablation of thrombus with antegrade flow (Figure 4C). Further balloon angioplasty achieved an excellent angiographic result, with brisk antegrade flow, three-vessel distal runoff, and no evidence of distal embolization (Figures 4D–4F). This case demonstrates the efficacy of laser atherectomy for treatment of acute thrombosis, even in long-segment graft thrombosis. Close attention to slow advancement of the laser at 1 mm/sec helps maximize thrombus ablation and minimize the risk of distal embolization.

FUTURE DIRECTIONS

Eccentric debulking using the Turbo-Power laser is an effective tool for treatment of many complex femoropopliteal pathologies, including in-stent restenosis, long-segment femoropopliteal occlusions, and graft thrombosis. Future studies will provide real-world data on clinical outcomes with this and other atherectomy devices. Of special interest is the possible combined application of laser atherectomy with DCB technology. Although not currently approved for this indication in the United States, DCBs have demonstrated improved outcomes for treatment of FP-ISR compared to historical outcomes with balloon angioplasty in a few studies.^{8,9} The Turbo-Power laser provides better acute luminal gain in FP-ISR, which may make it a good preparation for DCBs. Although a small study has shown a possible benefit of combined laser atherectomy with DCB angioplasty for the treatment of FP-ISR,¹⁰ additional studies are necessary to determine the benefits of this combined treatment approach for FP-ISR and other de novo femoropopliteal disease. ■

1. Tosaka A, Soga Y, Iida O, et al. Classification and clinical impact of restenosis after femoropopliteal stenting. *J Am Coll Cardiol.* 2012;59:16–23.
2. Armstrong EJ, Singh S, Singh GD, et al. Angiographic characteristics of femoropopliteal in-stent restenosis: association with long-term outcomes after endovascular intervention. *Catheter Cardiovasc Interv.* 2013;82:1168–1174.
3. Dippel EJ, Makam P, Kovach R, et al. Randomized controlled study of excimer laser atherectomy for treatment of femoropopliteal in-stent restenosis. *JACC Cardiovasc Interv.* 2015;8:92–101.
4. Armstrong EJ, Thiruvoipati T, Tanganyika K, et al. Laser atherectomy for treatment of femoropopliteal in-stent restenosis. *J Endovasc Ther.* 2015;22:506–513.
5. Scheinert D, Laird JR Jr, Schroder M, et al. Excimer laser-assisted recanalization of long, chronic superficial femoral artery occlusions. *J Endovasc Ther* 2001;8:156–166.
6. Steinkamp HJ, Rademaker J, Wissgott C, et al. Percutaneous transluminal laser angioplasty versus balloon dilation for treatment of popliteal artery occlusions. *J Endovasc Ther.* 2002;9:882–888.
7. Laird JR, Zeller T, Gray BH, et al. Limb salvage following laser-assisted angioplasty for critical limb ischemia: results of the LACI multicenter trial. *J Endovasc Ther.* 2006;13:1–11.
8. Virga V, Stabile E, Biamino G, et al. Drug-eluting balloon for the treatment of superficial femoral artery in-stent restenosis: 2-year follow-up. *JACC Cardiovasc Interv.* 2014;7:411–415.
9. Krankenberg H, Tubler T, Ingwersen M, et al. Drug-coated balloon versus standard balloon for superficial femoral artery in-stent restenosis: the randomized femoral artery in-stent restenosis (FAIR) trial. *Circulation.* 2015;132:2230–2236.
10. Gandini R, Del Guidice C, Merolla S, et al. Treatment of chronic SFA in-stent occlusion with combined laser atherectomy and drug-eluting balloon angioplasty in patients with critical limb ischemia: a single-center, prospective, randomized study. *J Endovasc Ther.* 2013;20:805–814.

Ehrin J. Armstrong, MD, MSc

Division of Cardiology
University of Colorado School of Medicine
ehrin.armstrong@gmail.com

Disclosures: Consultant for Abbott Vascular, Boston Scientific Corporation, Cardiovascular Systems, Inc., Cook Medical, Medtronic, and Spectranetics Corporation.